



# The International Federation of Head and Neck Oncologic Societies

Current Concepts in Head and Neck Surgery and Oncology 2017



[www.ifhnos.net](http://www.ifhnos.net)



# The International Federation of Head and Neck Oncologic Societies

Current Concepts in Head and Neck Surgery and Oncology 2017

## Stump the Faculty

Ashok Shaha

# Stump the Faculty

**Moderator: Ashok Shaha, MD**

**1. *True or False:* Patient with 2 cm lower lip cancer in the midline should undergo bilateral elective supraomohyoid neck dissection to find the status of the lymph nodes.**

## 2. The best functional results achieved in a patient with T2 vocal cord cancer by:

- Endoscopic resection
- Partial laryngectomy
- Radiation therapy
- Combination of chemoradiation therapy

### **3. The best indication for organ preservation chemoradiation therapy is:**

- **T3 supraglottic larynx cancer involving the vocal cords**
- **Massive subglottic cancer**
- **T4 larynx cancer with cartilage destruction**
- **T3 hypopharyngeal cancer**
- **Carcinoma of the supraglottic larynx with involvement of base of tongue**

## 4. The most concerning complication of organ preservation (chemoradiation therapy) is:

- **Pancytopenia**
- **Grade IV mucositis**
- **Recurrent pneumonia**
- **Pharyngeal stricture**

**5. In a patient undergoing total laryngectomy for advanced laryngeal cancer after chemoradiation therapy, the best option to reduce of pharyngeal fistula is:**

- **Three layer primary pharyngeal closure**
- **Pectoral muscular flap**
- **Deltopectoral flap**
- **Pharyngeal and carotid protection with levator scapulae muscle**



6. ***True or False:*** In a patient presenting with esthesioneuroblastoma, invasion of the brain is a definite contraindication for craniofacial resection.

- True
- False

## **7. The appropriate indication in head and neck melanoma for sentinel node biopsy is:**

- Melanoma thickness below 0.5 mm**
- Melanoma thickness below 0.9 mm**
- Melanoma thickness between 1 – 1.5 mm**
- Melanoma thickness between 1.5 – 3.9 mm**
- Melanoma thickness more than 4 mm**

## 8. Prognostically, the worst head and neck sarcoma is:

- Low grade fibrosarcoma
- Osteogenic sarcoma
- Angiosarcoma
- Leiomyosarcoma

**9. The best evaluation of a patient with carcinoma of the floor of the mouth for decision regarding marginal mandibulectomy is:**

- **Dental films**
- **Panoramic x-ray**
- **Clinical evaluation**
- **CT or MRI scan**
- **Bone scan**

# 10. The incidence of malignant transformation in leukoplakia is:

- 2%
- 7%
- 13%
- 55%

# 11. The incidence of malignant transformation in erythroplakia is:

- 10%
- 25%
- 75%
- 99%

12. **True or False:** Vitamin A analogs have shown considerable reduction in the development of second primary tumors in patients presenting with head and neck squamous carcinoma.

- True
- False

# 13. The incidence of second primary cancer in patients presenting with index squamous cell carcinoma of the head and neck is:

- 50% for the first five years
- 3-4% every year for the first few years
- Highest incidence with lip cancer



**14. The overall incidence of synchronous second primary in head and neck cancer is:**

- 1%
- 55%
- 13%
- 25%

# Case Presentation

- 68 year old CEO presents with left neck mass, 2 cm. Fine needle aspiration biopsy positive for metastatic sq ca (HPV +).
- No identifiable primary
- TORS of the base of tongue negative
- Left modified neck dissection
- 1 positive neck node – no extranodal spread.
- Further treatment
  - » Observation
  - » Radiation to the neck and the mucosa
  - » Radiation to the neck only
  - » Chemoradiation therapy

# Case Presentation

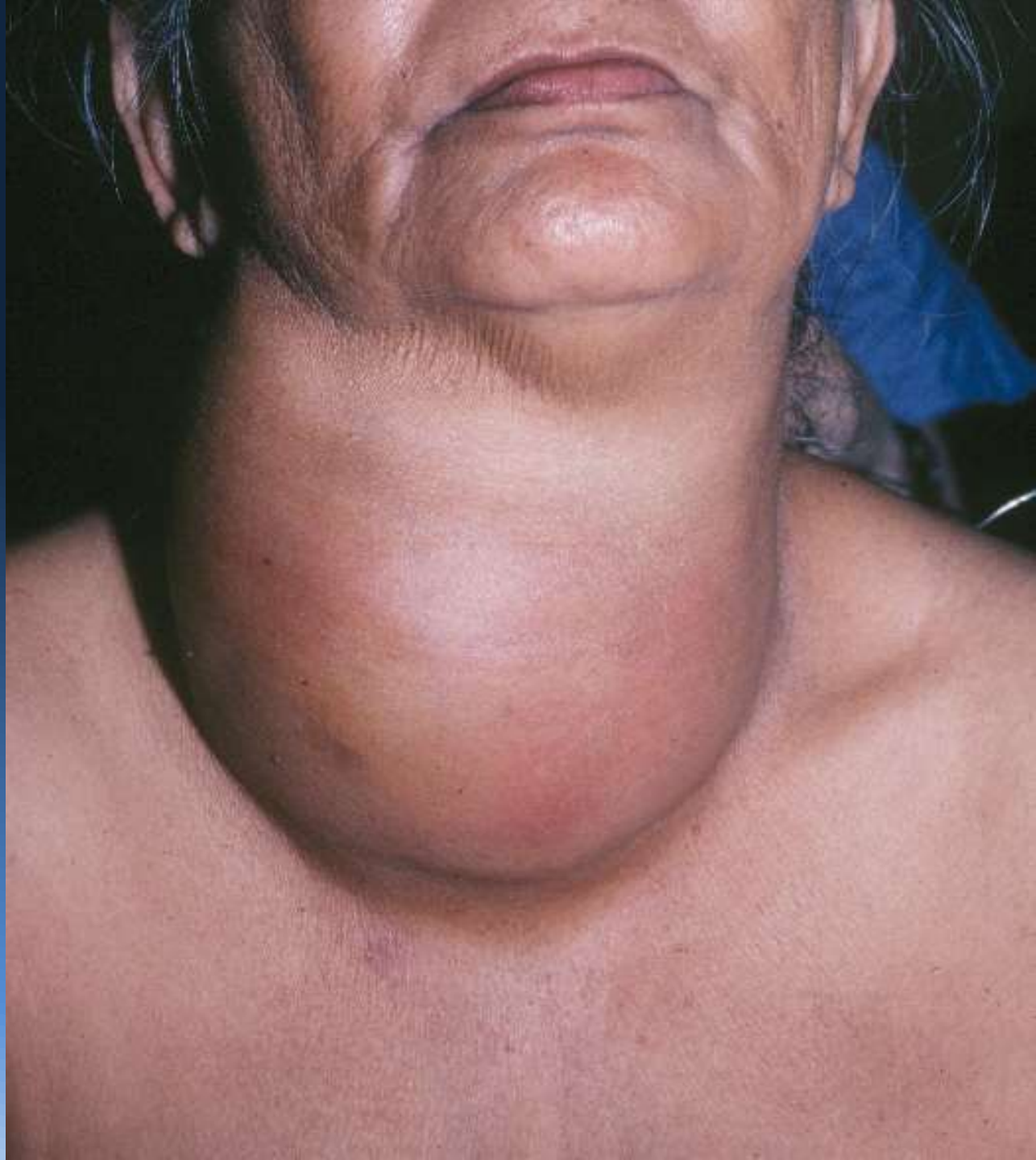- 68 year old retired Head and Neck Surgeon presents with 8 month history of right tonsil lesion 2.4 cm
- Biopsy- (HPV+) Sq Ca
- Imaging- Negative for the neck
- Treatment Choices

# Case Presentation

- 55 year old litigation attorney presents with lesion involving the right tonsil 1.6 cm.
- Biopsy Sq Ca (HPV+)
- Imaging: Negative Neck
  - Primary- R Tonsillar Irregularity
- Treatment Choices

# Case Presentation

- 67 year old nurse notices rapidly increasing thyroid mass for 6 weeks
- Hoarseness for 3 weeks
- Diffuse firm mass, fixed to the central compartment of neck with paralyzed right vocal cord
- FNA suggestive of anaplastic thyroid ca
  - Diagnosis
  - Work up
  - Treatment

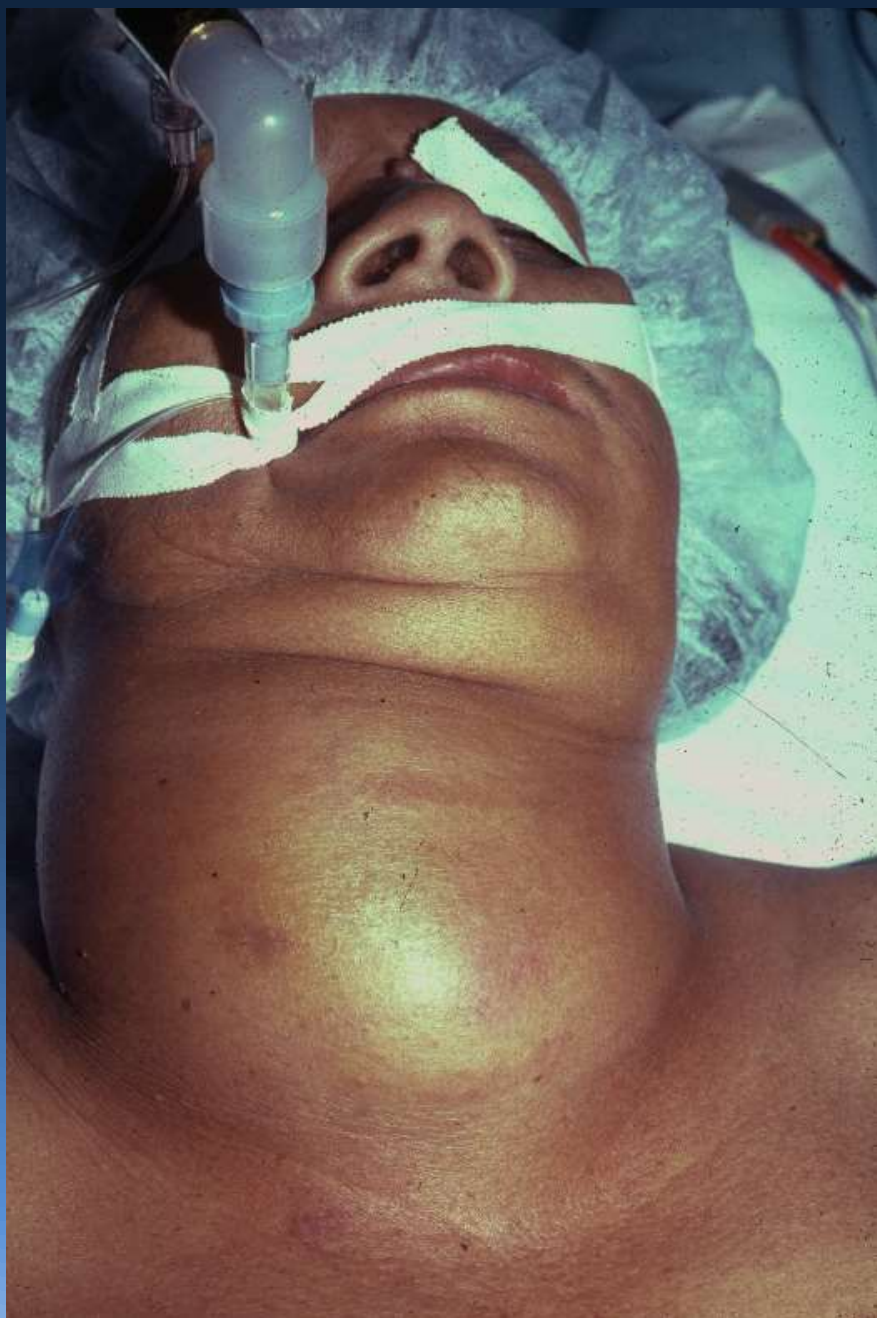



# Case Presentation

- Soon after admission patient has increasing difficulty in breathing with stridor
  - Airway management
  - Further treatment
  - Pathology
  - Prognosis







# Case

- **38 year old maxillofacial surgeon presents with ulcerated lesion on left side of the tongue 1.8cm: biopsy T<sub>1</sub>N<sub>0</sub>M<sub>0</sub>**
- **Role of sentinel node biopsy**

- **Role of Superselective Neck Dissection**
- **Level II and III only**

- Oral Cancer – Margins of Resection, How Much?

- Frozen Section / From the Specimen or From the Patient

- Tumor Margins –  
Pushing Margins

- Infiltrating  
Margins

- Role of Depth of Tumor
- What is a cutoff for elective node dissection?

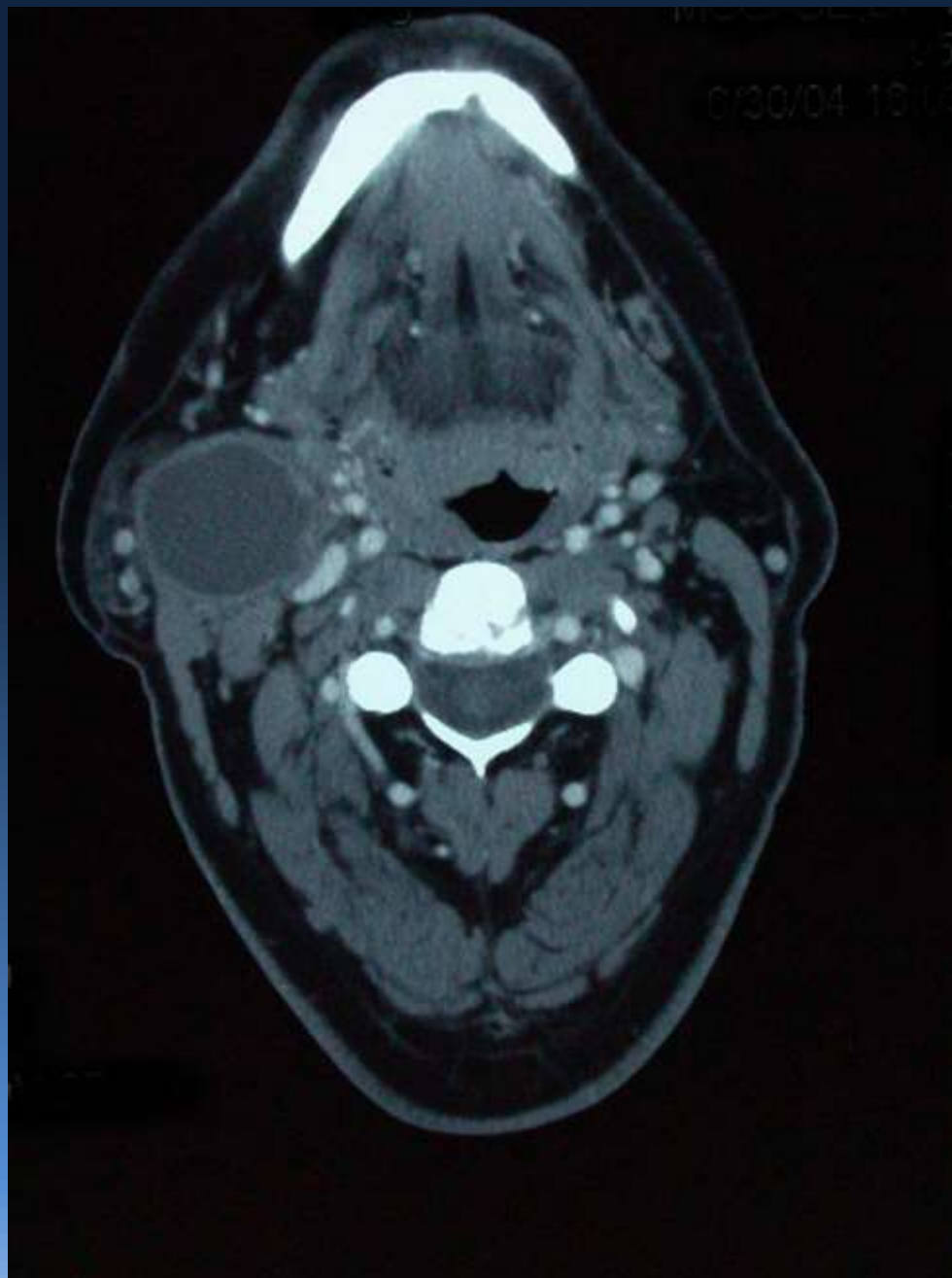
## Case #22

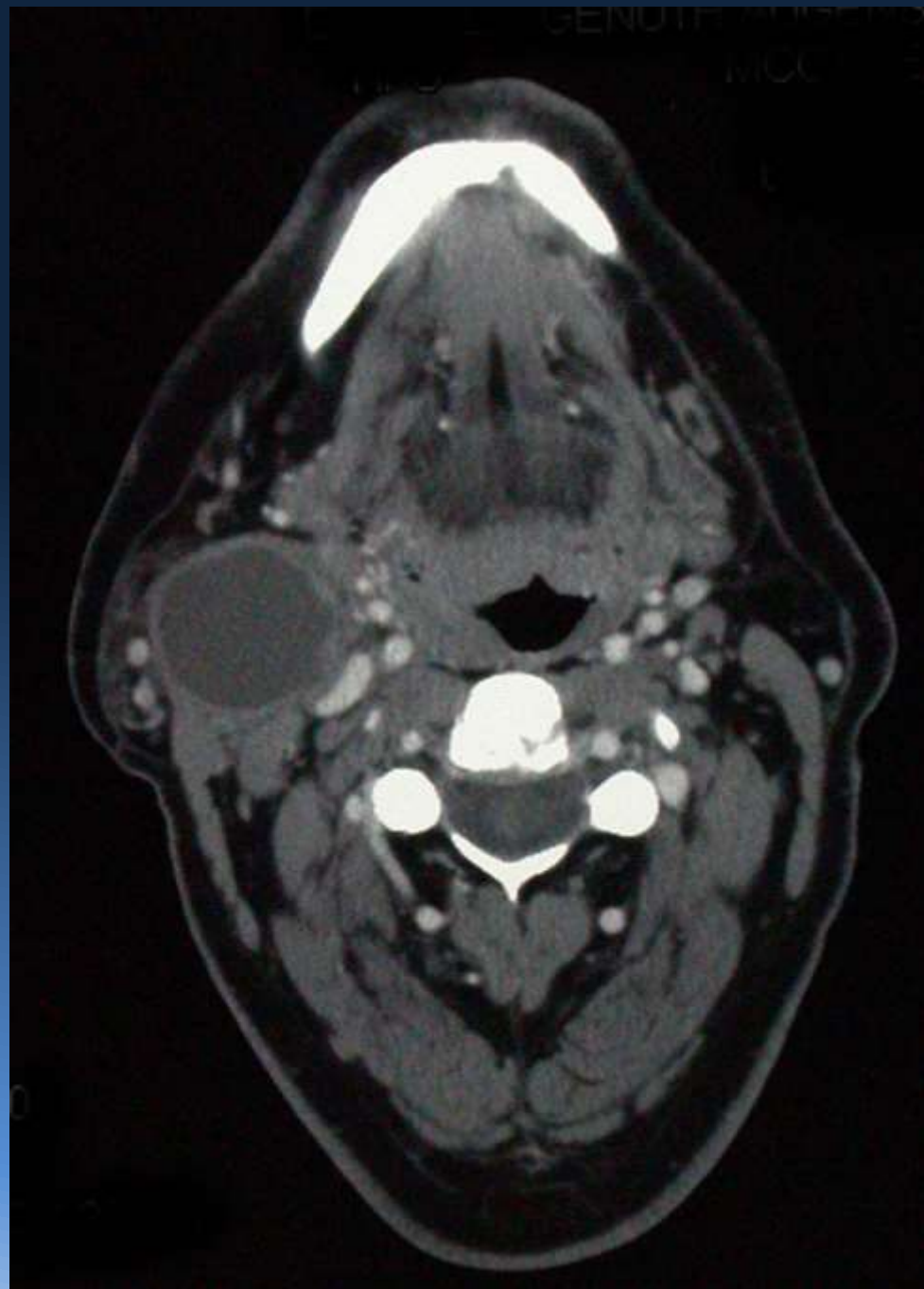
- 65 year old retired criminal lawyer had undergone total thyroidectomy for 4 cm medullary carcinoma of the thyroid two years back. Two paratracheal nodes were positive at initial surgery.
- Pt presents with rising calcitonin of 6234 pg/mL
- Further work up and management

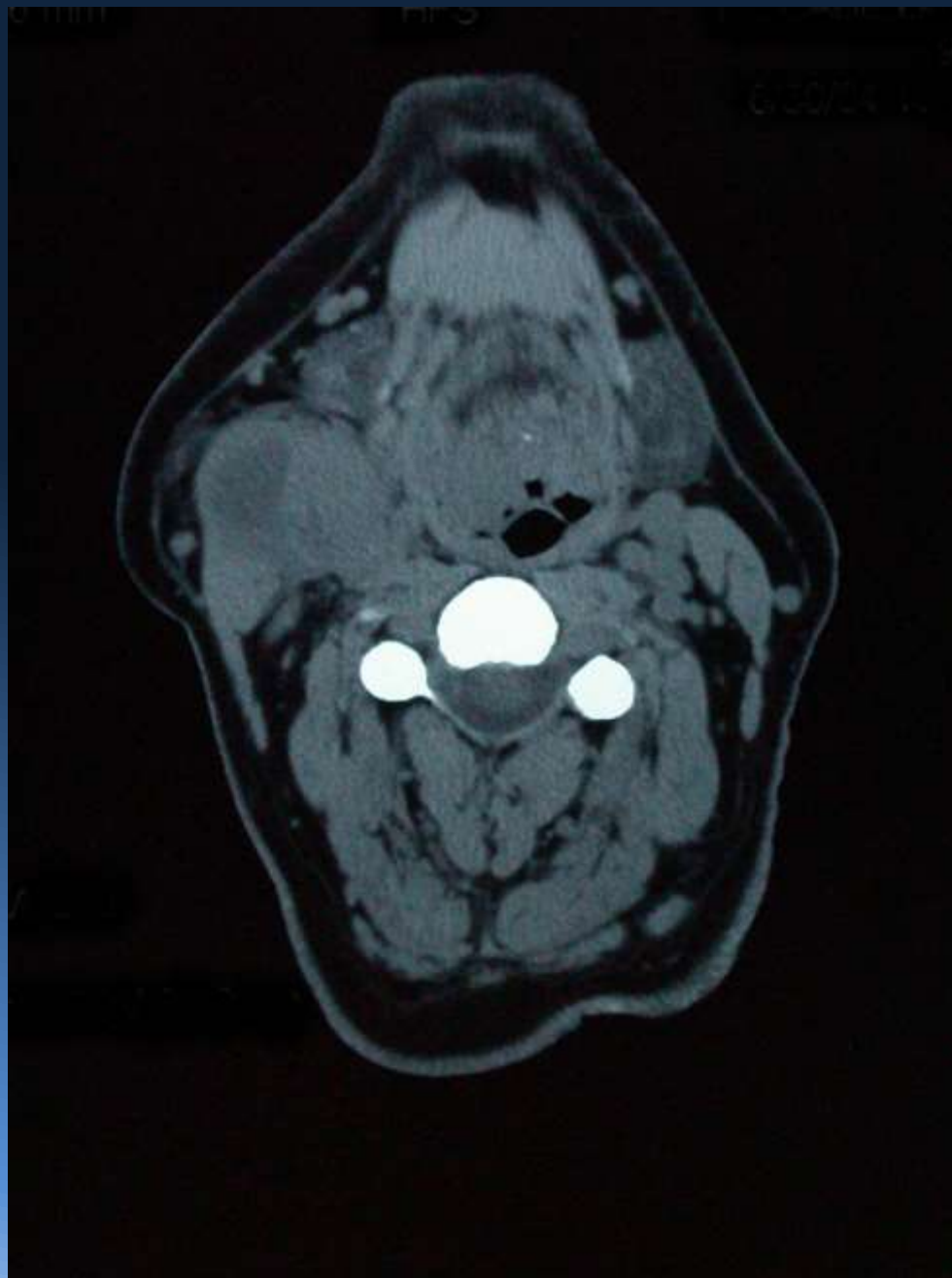# Case Presentation

- **56 year old male presents with right neck mass – 3 months**
- **Patient was diagnosed as branchial cyst outside based on his CT report**
- **He complains of vague discomfort in the right neck**

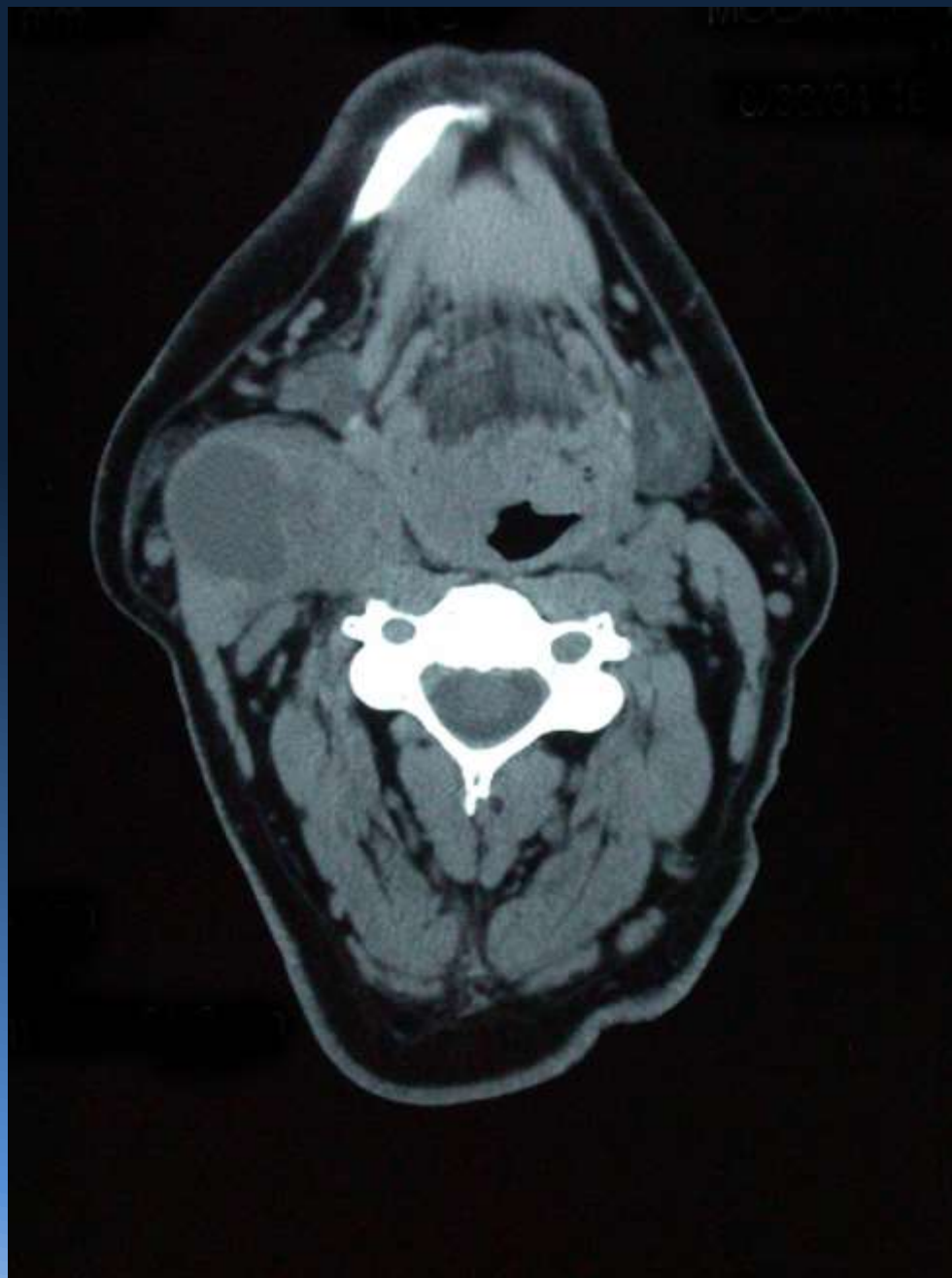


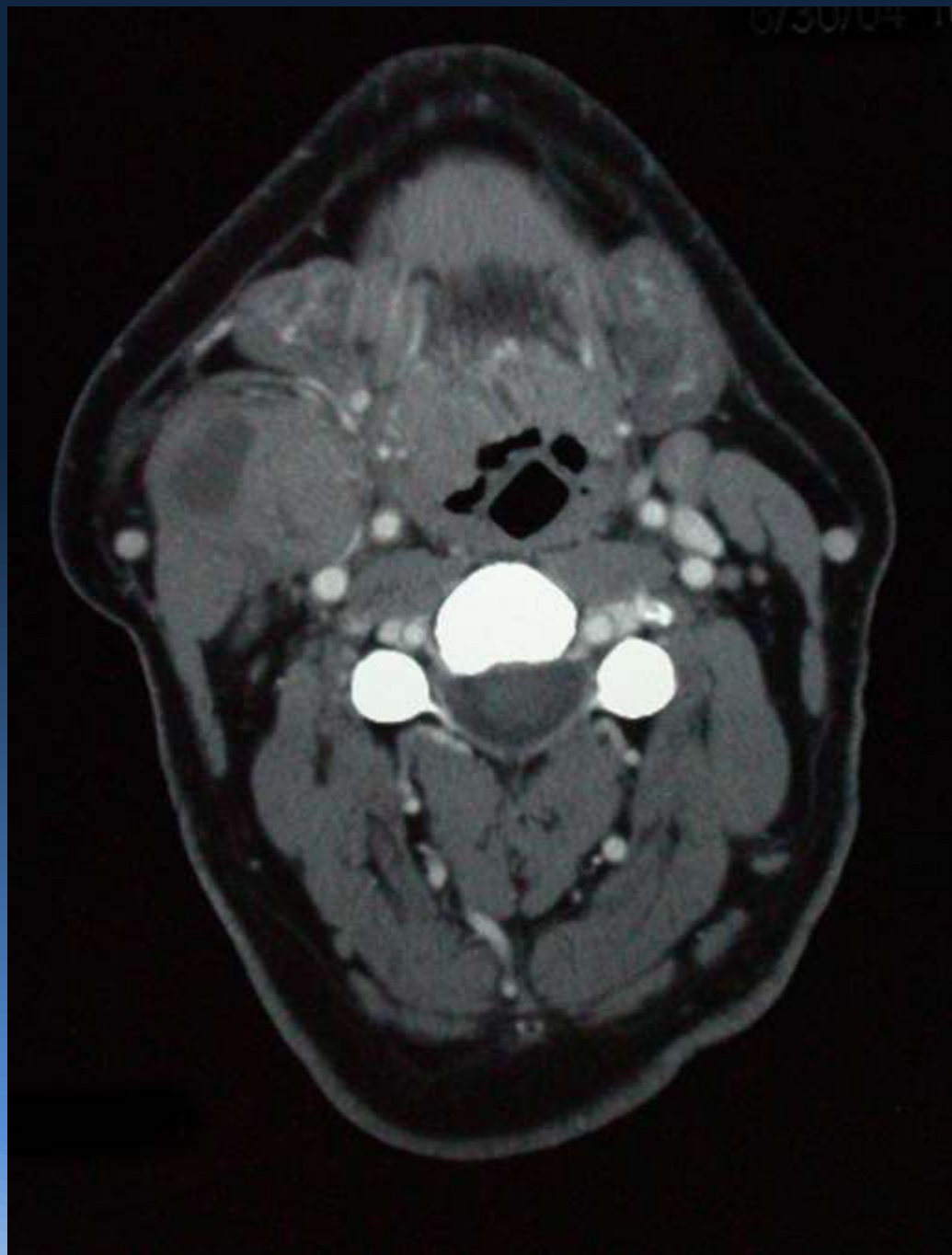




- **P/E 4x4 cm mass right, Level II & III**
- **Lesion noted at the right base of the tongue**

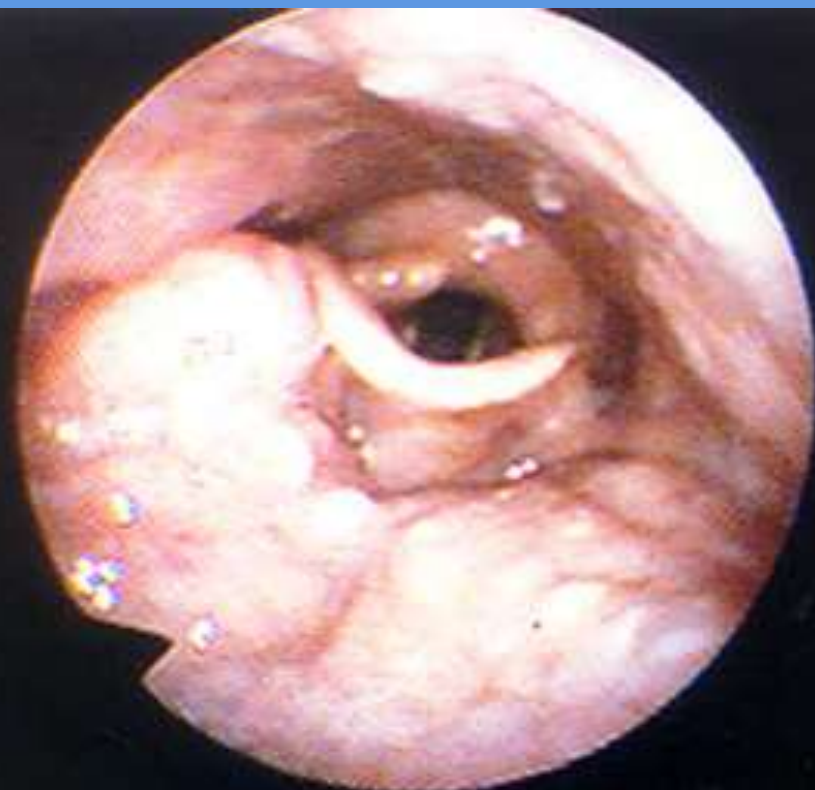
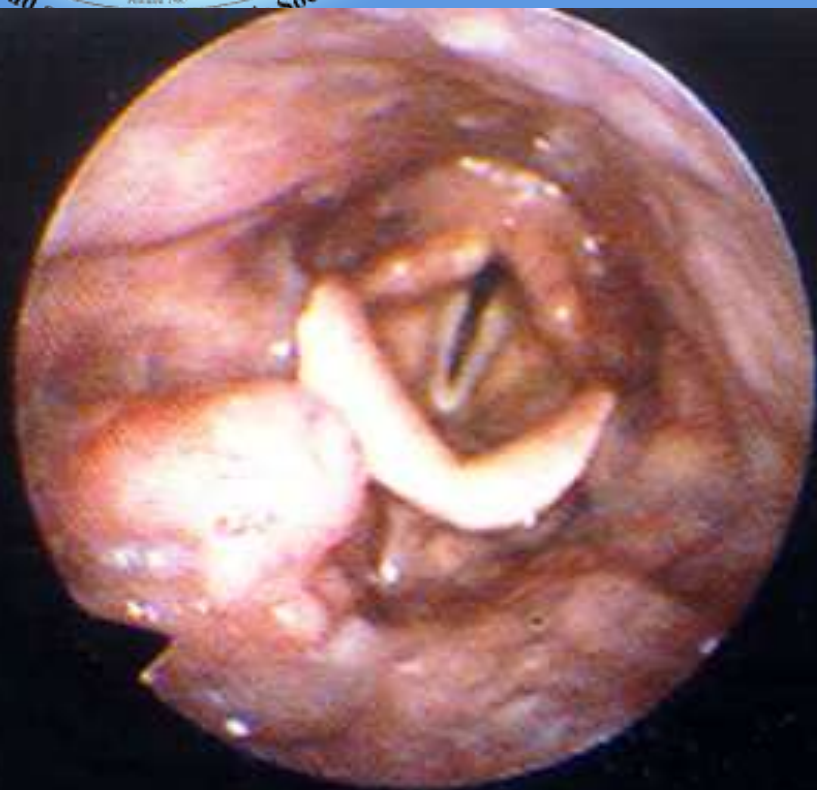
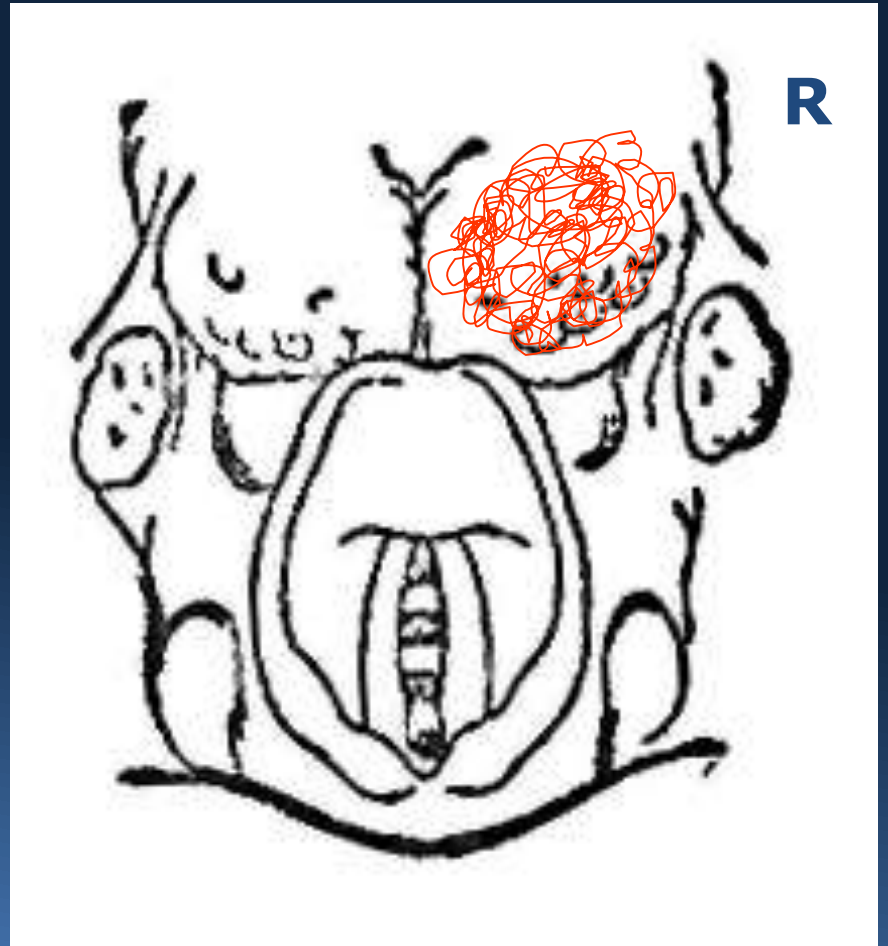
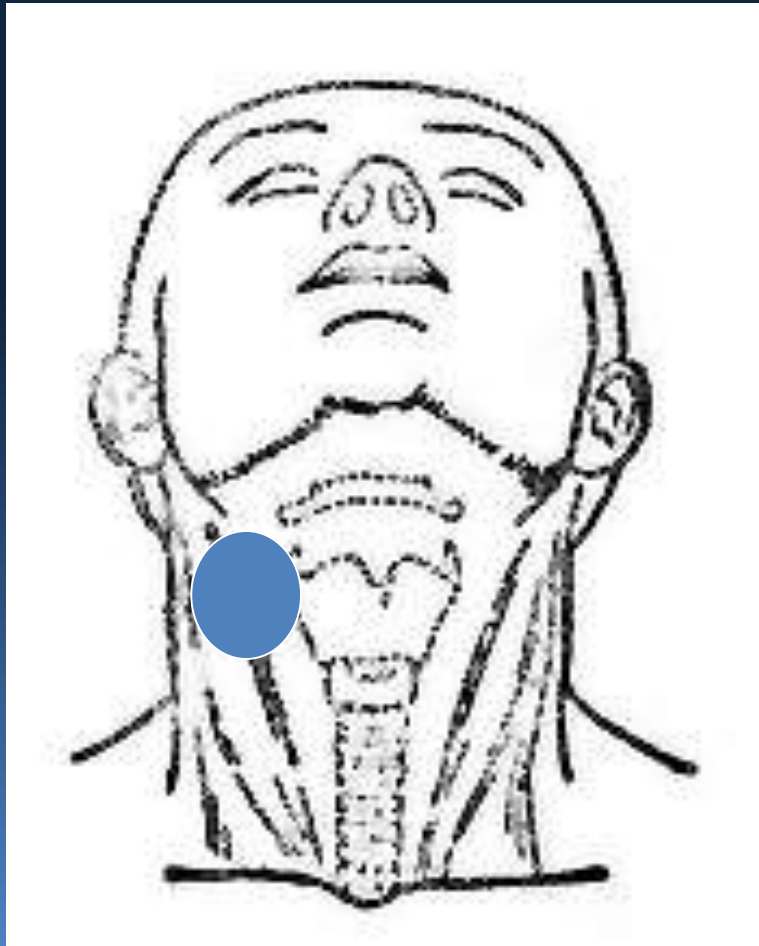






# The International Federation of Head and Neck Oncologic Societies







# Choice of Treatment

## Cancer of the Base of the Tongue (T2 N2 M0)

1. Concurrent chemoradiation therapy
2. Neck dissection followed by radiation therapy
3. Primary surgery for the neck and base of the tongue with postoperative radiation therapy
4. Planned radiation therapy, neck dissection with brachytherapy

# Case Presentation

1. 54 yo retired litigation attorney presents with left neck mass measuring 2.5 cm
2. Undergoes excisional biopsy at an outside institution with a diagnosis of metastatic squamous cell carcinoma
3. Postoperative CT scan of the neck is negative

**Patient now presents for further opinion**

# Case Presentation

The same litigation attorney had presented with a fine needle aspiration biopsy of a left neck mass and a diagnosis of squamous cell carcinoma

**Further work-up and definitive treatment?**

# Case Presentation

- **78 year old female, otherwise in reasonably good health presents with shortness of breath, hoarseness of voice and considerable dysphagia**
- **Examination of the neck was negative; however, examination of the larynx and hypopharynx revealed a large tumor obstructing the view of the endolarynx, paralyzed right vocal cord with extensive disease involving the entire right side of the pyriform sinus with extension of the disease into the postcricoid area**

**Treatment Choices:**



**The rule of 20: Only 20% of the people will remember 20% of what you said 20 minutes after your lecture.**

Shaha's Aphorisms

**Shaha's #1 Rule: You cannot  
finish until you start.**

Shaha's Aphorisms

“When I was younger, I always told the residents that the first sign of senility in a surgeon is when he demonstrates an interest in surgical history.”

*--Leo A. Gordon*



“The decision is more  
important than the  
incision.”

“When technology is the  
Master, the result is  
Disaster.”

“Six Ps:  
Proper planning and  
preparation prevents poor  
performance.”

“A surgeon is sometimes right, sometimes wrong, but never uncertain.”

**During the difficult part of the operation, step out of the operating room for an emergency phone call or to have an important meeting with the Chairman or visiting professor.**

Shaha's Aphorisms

**Publish your results before the  
tumor recurs.**

Shaha's Aphorisms

**Best surgical sense is your intuition.**

Shaha's Aphorisms

**Academic Surgeon: Talk more,  
operate less.**

Shaha's Aphorisms



**Two ways to control the bleeding, the first is in the operating room and the second is in the middle of the night.**

Shaha's Aphorisms

**Irrigate the wound with  
Betadine, it hides the blood  
loss!**

Shaha's Aphorisms

**In surgery, the best  
instruments are fingers as  
they are connected to the  
brain.**

Shaha's Aphorisms

**When you don't know what to  
do in the operating room, use  
irrigation.**

**When you don't know what to  
do in the ICU, use steroids.**

Shaha's Aphorisms

**Four Stages in the life of a Surgeon: How to operate? When to operate? When not to operate? And how to dump the case on someone else.**

Shaha's Aphorisms

“You recognize a surgeon or an OB/GYN because he has blood on his shoes, a urologist because he has urine on his, and an anesthetist because on his you see spots of coffee on his.”

*--Bernard Cristalli*



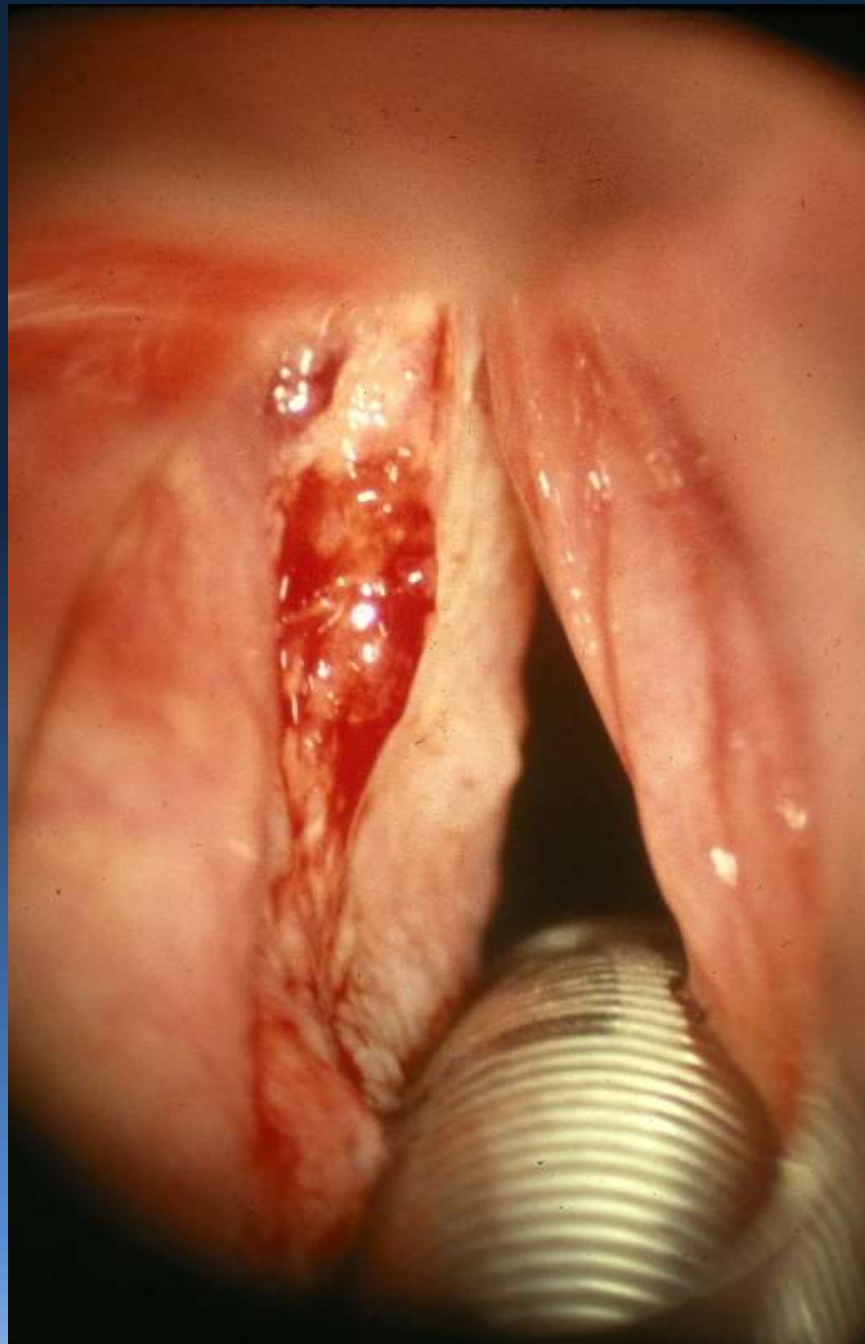




# Case Presentation

- 54 year old practicing lawyer presents with hoarseness of voice for four months duration
- No other specific symptoms, except mild hoarseness
- Physical examination of the neck was negative
- Fiberoptic laryngoscopy revealed a lesion involving the right middle portion of the vocal cord extending almost up to the anterior commissure but not involving the anterior commissure
- The biopsy reveals infiltration squamous cell carcinoma

## Treatment Choices:



# Case Presentation

1. 32 yo head and neck surgeon had a lesion in the left lateral aspect of the tongue measuring 1 cm x 1 cm
2. Preoperative work-up, including a CT scan was negative
3. Patient underwent a wide excision at an outside institution, which was reported to show SCC well differentiated, no perineural or perivascular invasion, margins are negative and satisfactory. The depth of the lesion measures 5 mm.

**Patient now presents for further opinion:**

- Further investigations
- What about the neck?

# Case Presentation

- 1. 32 year old psychiatrist underwent partial glossectomy with a tumor measuring 2 cm in dimension and 1.3 cm in depth with tumor islands and negative margins**
- 2. The neck revealed only 1 positive node with no extranodal spread**

**Further  
treatment:**

# Case Presentation

1. 44 yo patient presents with sore throat
2. Clinical examination reveals right tonsil lesion measuring 1.8 cm
3. Biopsy of the lesion shows squamous cell carcinoma, HPV positive
4. Clinically and radiologically there are no enlarged lymph nodes

**Treatment  
choices?**

# Case Presentation

1. 49 yo gentleman presents with T3 tonsil cancer. The lesion is approximately 4 cm, but does not appear to be adherent to the mandible.
2. Radiologically there are no enlarged lymph nodes
3. HPV positive

**Treatment choices?**

# Case Presentation

- 1. 64 yo gentleman presents with a very advanced carcinoma of the right tonsil with extension into the soft palate with adherence to the mandible.**
- 2. Clinically there are suspicious lymph nodes in the right neck**

**Treatment choices?**

# Case Presentation

- 1. 73 yo gentleman presents with advanced carcinoma of the hypopharynx with a paralyzed vocal cord on the right side.**
- 2. Clinically, radiologically, and endoscopy reveals a T4 hypopharyngeal cancer with suspicious lymph nodes in the right neck. The lesion does not appear to involve the cartilage, but there is soft tissue and parapharyngeal extension of the disease.**

**Treatment choices?**



# Case #8

1. 73 yo male presents with a T1N2 base of tongue carcinoma
  2. His metastatic disease is at level II in the right neck
  3. Patient received chemoradiation therapy as definitive treatment
  4. 8 weeks after treatment he has vague fullness in the region of his N2 disease, however there are no suspicious findings in the base of the tongue
- Management of the neck after chemoradiation therapy

# Case Presentation

- 65 year old male undergoes surgery for cancer of the floor of the mouth with multiple positive nodes and gross extranodal extension
- T(3) N(2) M(0)
- Postoperative radiation or  
Postoperative chemoradiation?

# Case Presentation

- 1. 72 yo male presented to an outside institution with T2N2 carcinoma of the base of tongue**
- 2. He received chemoradiation therapy at an outside institution to MSKCC with odynophagia**
- 3. 4 weeks after the conclusion of his chemoradiation therapy, physical examination reveals ulceration in the base of the tongue and the area is difficult to evaluate**
  - Further work-up
  - Timing of the work-up
  - Timing of endoscopy
  - To what extent should a biopsy of the base of tongue be performed?

# Case Presentation

1. 65 yo professor of history presents with carcinoma of the tonsil
2. Clinically the tumor is deeply infiltrating into the tonsil and appears to be T2N2M0

**Treatment choices:**

# Case Presentation

- 1. 60 yo male with cirrhosis of the liver presents with T3 tongue cancer on the lateral aspect of the left side of the tongue**
  - 2. The tumor measures 4.5 cm**
  - 3. This is readily accessible through the open mouth for partial glossectomy and primary closure**
  - 4. Clinically the depth of the tumor is approximately 1.2 cm**
- 
- How would you manage the neck in this patient which is clinically and radiologically negative?**

# Case Presentation

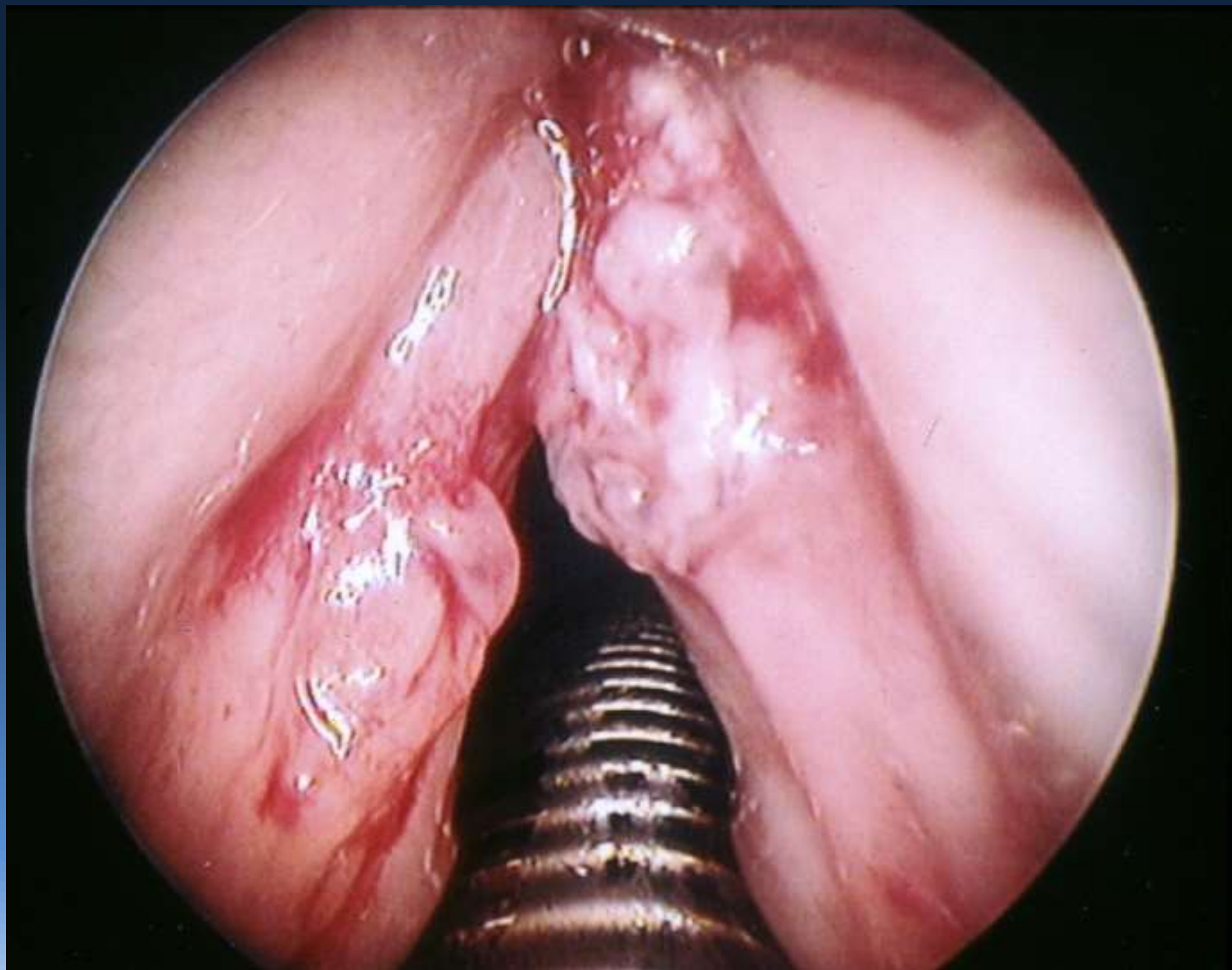
- 1. 62 yo female presents with a level II lymph node in the right neck**
- 2. FNAB was suggestive of metastatic adenocarcinoma**

**Further work-up and treatment:**

# Case #16

- 63 year old cardiothoracic surgeon presents with sore throat, mild pain in the laryngeal area and hoarseness of voice
- Physical examination of the neck was negative
- Examination of the larynx reveals exophytic and endophytic lesion involving the left cord with extension of the disease into the ventricle
- There is restricted movement of the vocal cord even though the vocal cord itself appears to be mobile
- There is no subglottic extension of the disease

## Treatment Choices:





# Case Presentation

1. 48 yo male presents with a 3 cm right neck node. FNAB is reported to be metastatic squamous cell carcinoma.
2. Entire work-up is negative

## **Treatment of choice:**

1. Radiation therapy alone
2. RMND and RT
3. Chemoradiation therapy
4. Excision of the neck mass and RT

# Case Presentation

1. The same patient had a biopsy-proven tonsil cancer which is T1 and is positive for HPV

**Treatment of  
choice?**

# Case Presentation

## Chemoradiation Failure Larynx Cancer

- 69 year old female with T(3) N(0) M(0) receives RT and chemo.
- Six months later patient comes back with increasing hoarseness and mild stridor

## Work-up and Management:

# Case Presentation

1. 75 yo female presents with dysphagia, weight loss and pain in the throat
2. Examination of the neck was negative and office examination of the head and neck and laryngopharyngeal area was also negative
3. Patient was brought to the OR and a 17 cm exophytic semi-obstructing lesion in the cervical esophagus was found

## **Treatment of choice:**

- Surgery including laryngopharyngectomy and jejunal interposition
- Radiation therapy
- Radiation and chemotherapy
- Endoscopic U/S
- Further evaluation





# The International Federation of Head and Neck Oncologic Societies

Current Concepts in Head and Neck Surgery and Oncology 2017

## A SMALL TRUTH TO MAKE LIFE

100%

**If**

**A B C D E F G H I J K L M N O P Q R S T U V W X Y Z**

**is equal to**

**1 2 3 4 5 6 7 8 9 10 11 12 13 14 15 16 17 18 19 20 21 22 23 24 25 26**

## Hard Work

H+A+R+D+W+O+R+K

8+1+18+4+23+15+18+11 = 98%

## Knowledge

K+N+O+W+L+E+D+G+E

11+14+15+23+12+5+4+7+5 = 96%



**Love**

**L+O+V+E**

**12+15+22+5 = 54%**

**Luck**

**L+U+C+K**

**12+21+3+11 = 47%**

( don't most of us think this is the most important ??? )

Then what makes **100%** ?

Is it Money ? ... **NO !!!**

M+O+N+E+Y

13+15+14+5+25 = **72%**

Leadership ? ... **NO !!!**

L+E+A+D+E+R+S+H+I+P

12+5+1+4+5+18+19+9+16 = **89%**

**Every problem has a solution,  
only if we perhaps change our  
attitude.**

**To go to the top,  
to that 100%,  
what we really need to go  
further... a bit more...**

# ATTITUDE

**A+T+T+I+T+U+D+E**

**1+20+20+9+20+21+4+5 = 100%**

**It is OUR ATTITUDE towards  
Life and Work that makes OUR  
Life **100% !!!****

# **ATTITUDE IS EVERYTHING**

## **Change Your Attitude ...**

## **And You Change Your Life ! ! !**

# • Partial Glossectomy – Types of Reconstruction

- Open – Secondary Healing
- Skin Graft
- Alloderm
- Pectoral Myocutaneous Flap
- Free Flap – Choice of Free Flap
- Nerve Graft

**Case I: 37 year old medical oncologist  
presents with T2NoMo Lateral of tongue  
Ca**

**A) Pre-op work up – primary /  
neck**

**B) At the time of neck dissection-  
suspicious node at Level II**

- **Change of Strategy?**

**C)? Level IV**

# Case I: 37 year old medical oncologist presents with T<sub>2</sub>NoMo Lateral of tongue Ca

## D. How do you do partial glossectomy:

- Knife/ Scissors
- Electrocautery
- Omniguide Laser
- Harmonic

## Closure



# **Case I: 37 year old medical oncologist presents with T<sub>2</sub>NoMo Lateral of tongue Ca**

**E. Final Path: 4mm deep, 1 positive node- Depth Consensus**

# Case I: 37 year old medical oncologist presents with T<sub>2</sub>NoMo Lateral of tongue Ca

## F. Pathological features of Primary

# Case I: 37 year old medical oncologist presents with T<sub>2</sub>NoMo Lateral of tongue Ca

## G. Post-Op Chemo RT? When?

# Case I: 37 year old medical oncologist presents with T<sub>2</sub>NoMo Lateral of tongue Ca

## H. Role of Brachytherapy?

# Case I: 37 year old medical oncologist presents with T<sub>2</sub>NoMo Lateral of tongue Ca

## I. Contralateral Neck Disease

# Case I: 37 year old medical oncologist presents with T<sub>2</sub>NoMo Lateral of tongue Ca

## I. Post-Op Follow-Up

Case 11: 55 year old professor  
of political science presents  
with T<sub>2</sub>NoMo Ca floor of the  
mouth:

- A) Evaluation of the mandible
- B) Decision about marginal /  
segmental

# Case III: 45 year old Judge presents with T<sub>4</sub>N<sub>1</sub>M<sub>0</sub> Carcinoma of the floor of the mouth requiring segmental resection

- Reconstruction primary / secondary
- A-O Plate
- Pectoral Myocutaneous Flap
- Free Flap – Soft tissue / Bone



# Case IV: 67 year old Accountant presents with T<sub>4</sub>N<sub>2</sub>M<sub>0</sub> carcinoma of the oral tongue requiring extended hemiglossectomy

- Post-Op RT
- Oral Cripple – Quality of Life

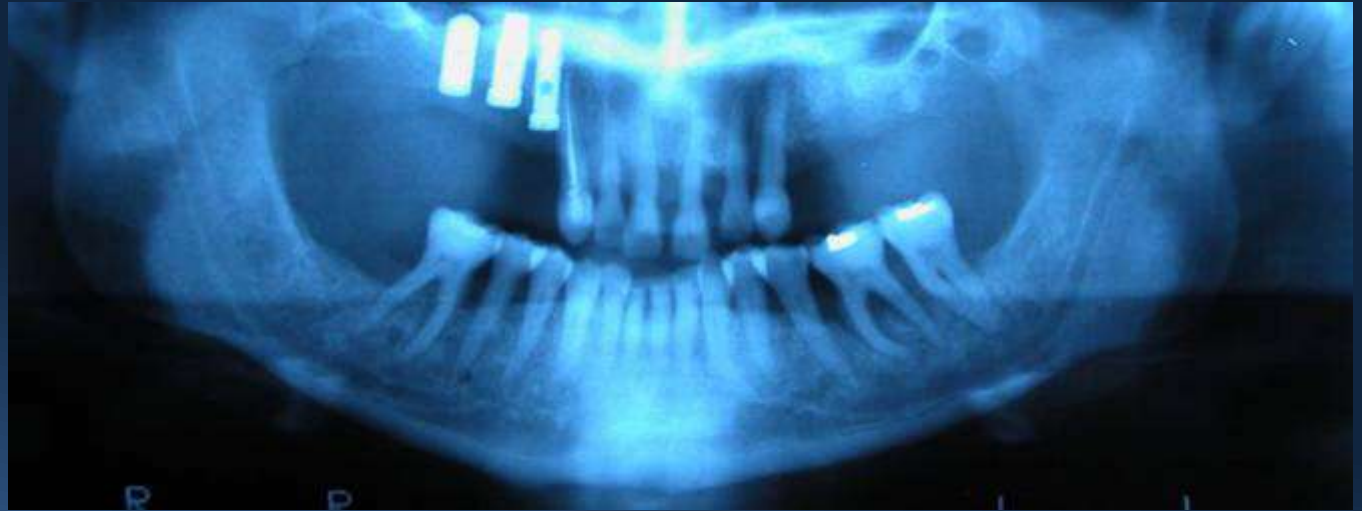
# Case V: 84 year old Grandfather presents with T<sub>4</sub>N<sub>2</sub>cMo carcinoma oral tongue

- Treatment choices:
- Radical Resection, Post-Op RT
- Chemo RT as a definitive treatment

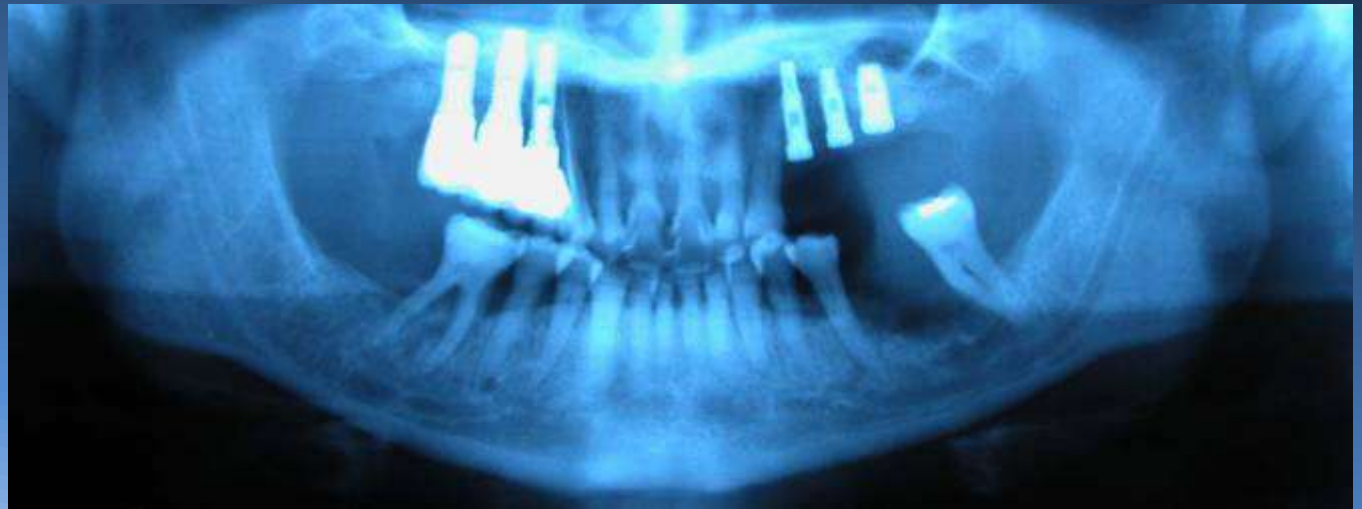Case VI: 64 year old female  
treated 5 years back with  
Chemo RT for Ca base of the  
tongue

# Osteoradionecrosis

May 2000

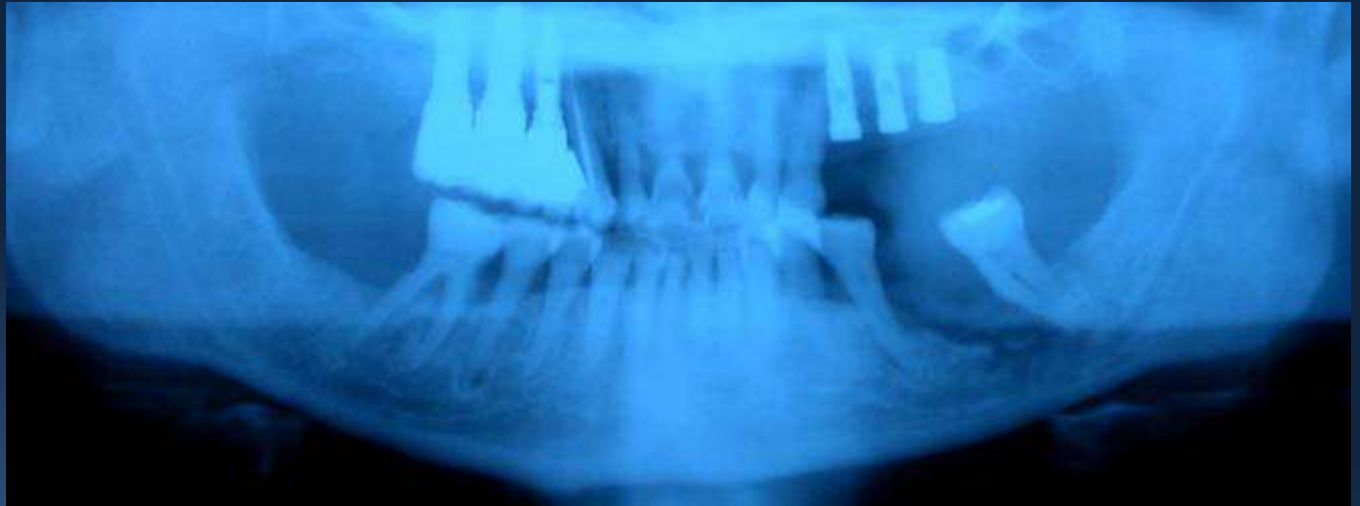


Jan 2001

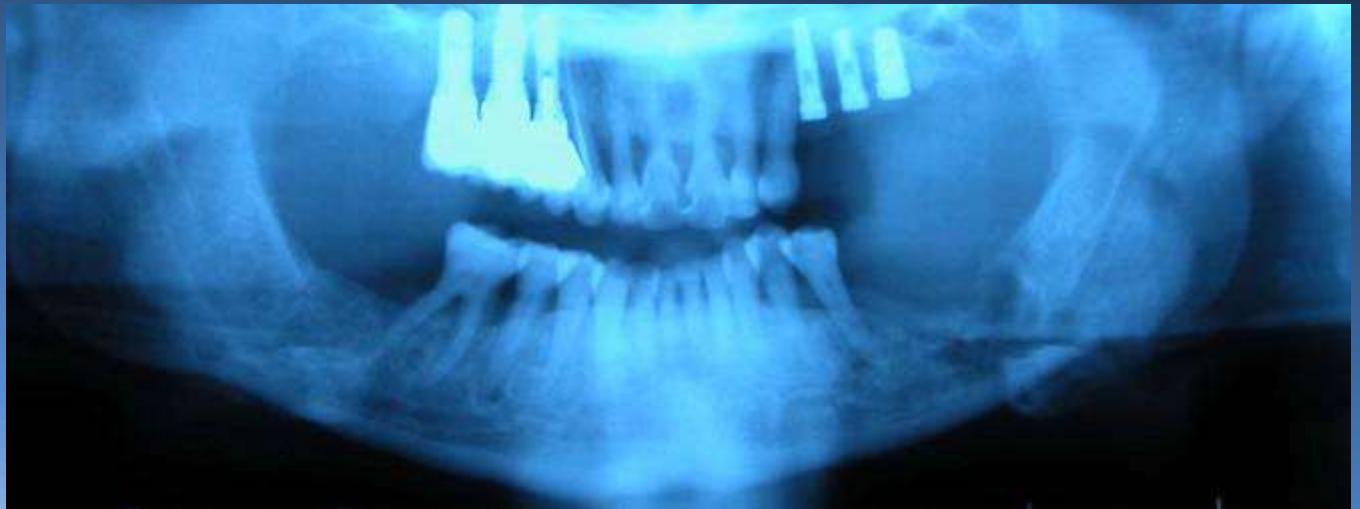

# Osteoradionecrosis

Sept 2001

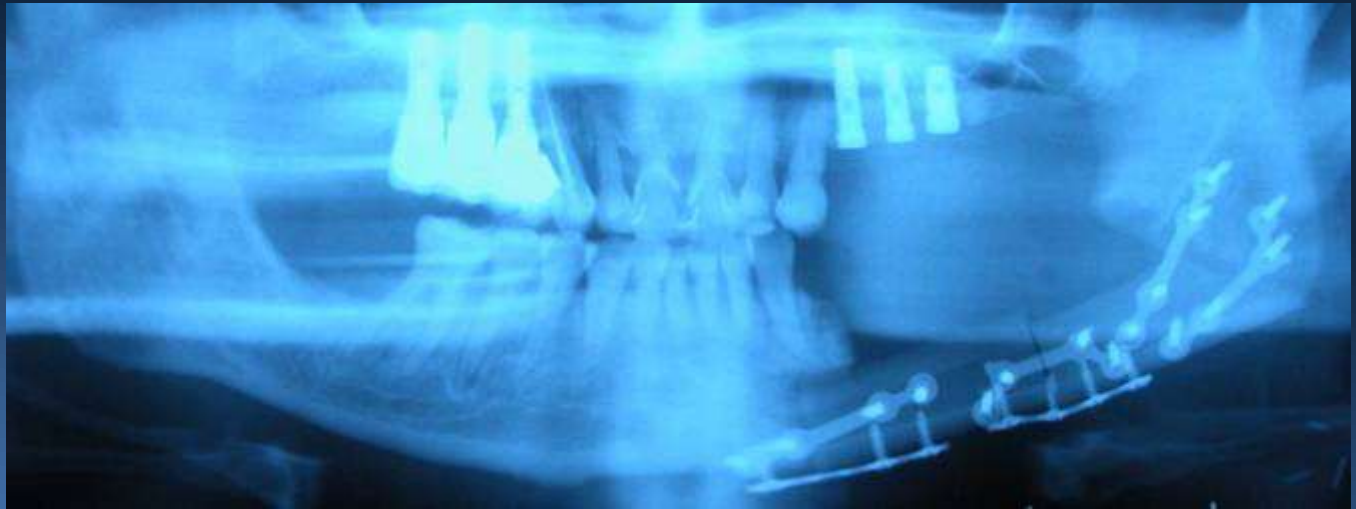


May 2002



# Osteoradionecrosis

June 2002





***True or False:*** Patient with 2 cm lower lip cancer in the midline should undergo bilateral elective supraomohyoid neck dissection to find the status of the lymph nodes.

# The most concerning complication of organ preservation (chemoradiation therapy) is:

- **Pancytopenia**
- **Grade IV mucositis**
- **Recurrent pneumonia**
- **Pharyngeal stricture**



**The best evaluation of a patient with carcinoma of the floor of the mouth for decision regarding marginal mandibulectomy is:**

- **Dental films**
- **Panoramic x-ray**
- **Clinical evaluation**
- **CT or MRI scan**
- **Bone scan**

# The incidence of malignant transformation in leukoplakia is:

- 2%
- 7%
- 13%
- 55%

# The incidence of malignant transformation in erythroplakia is:

- 10%
- 25%
- 75%
- 99%

***True or False:*** Vitamin A analogs have shown considerable reduction in the development of second primary tumors in patients presenting with head and neck squamous carcinoma.

- **True**
- **False**

# **The incidence of second primary cancer in patients presenting with index squamous cell carcinoma of the head and neck is:**

- **50% for the first five years**
- **3-4% every year for the first few years**
- **Highest incidence with lip cancer**

# The overall incidence of synchronous second primary in head and neck cancer is:

- 1%
- 55%
- 13%
- 25%

- 1. 32 yo head and neck surgeon had a lesion in the left lateral aspect of the tongue measuring 1 cm x 1 cm**
- 2. Preoperative work-up, including a CT scan was negative**
- 3. Patient underwent a wide excision at an outside institution, which was reported to show SCC well differentiated, no perineural or perivascular invasion, margins are negative and satisfactory. The depth of the lesion measures 5 mm.**

**Patient now presents for further opinion:**

- Further investigations**
- What about the neck?**

- 1. 32 year old psychiatrist underwent partial glossectomy with a tumor measuring 2 cm in dimension and 8 mm in depth**
- 2. The neck revealed only 1 positive node with no extranodal spread**

**Further  
treatment:**

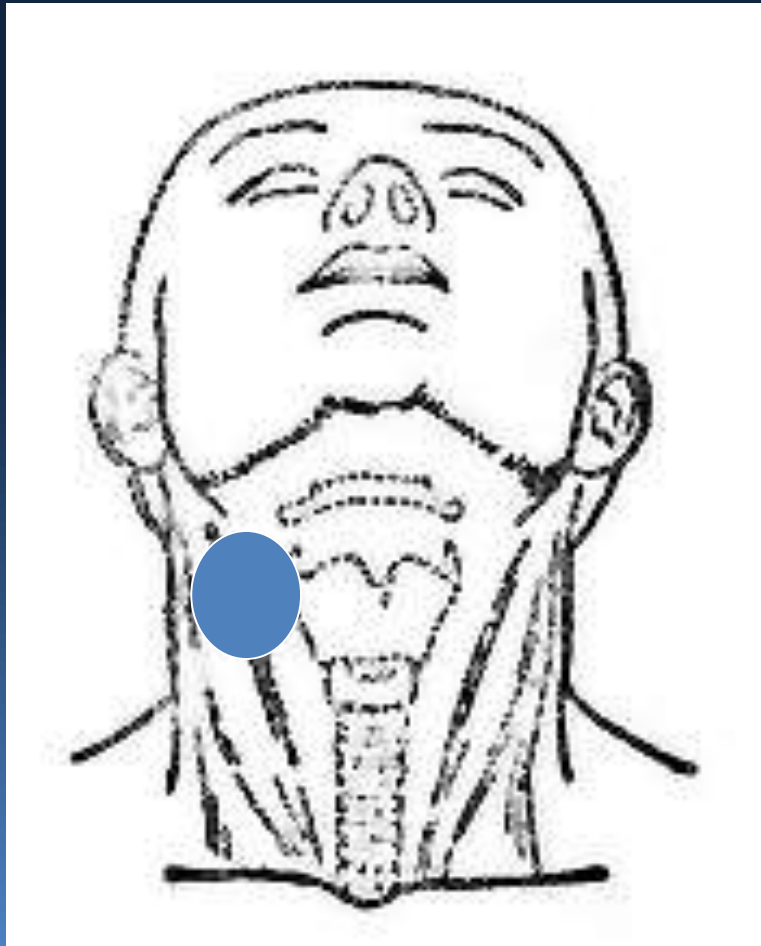






# The International Federation of Head and Neck Oncologic Societies





# **Choice of Treatment**

## **Cancer of the Base of the Tongue (T2 N2 M0)**

- 1. Concurrent chemoradiation therapy**
- 2. Neck dissection followed by radiation therapy**
- 3. Primary surgery for the neck and base of the tongue with postoperative radiation therapy**
- 4. Planned radiation therapy, neck dissection with brachytherapy**

1. 44 yo patient presents with sore throat
2. Clinical examination reveals right tonsil lesion measuring 1.8 cm
3. Biopsy of the lesion shows squamous cell carcinoma, HPV positive
4. Clinically and radiologically there are no enlarged lymph nodes

**Treatment  
choices?**

1. 49 yo gentleman presents with T3 tonsil cancer. The lesion is approximately 4 cm, but does not appear to be adherent to the mandible.
2. Radiologically there are no enlarged lymph nodes
3. HPV positive

**Treatment choices?**

**Shaha's #1 Rule: You cannot  
finish until you start.**

Shaha's Aphorisms



**During the difficult part of the operation, step out of the operating room for an emergency phone call or to have an important meeting with the Chairman or visiting professor.**

Shaha's Aphorisms



**Publish your results before the  
tumor recurs.**

Shaha's Aphorisms

**Best surgical sense is your intuition.**

Shaha's Aphorisms

**The rule of 20: Only 20% of the people will remember 20% of what you said 20 minutes after your lecture.**

Shaha's Aphorisms

**Academic Surgeon: Talk more,  
operate less.**

Shaha's Aphorisms

**Two ways to control the bleeding, the first is in the operating room and the second is in the middle of the night.**

Shaha's Aphorisms

**Irrigate the wound with  
Betadine, it hides the blood  
loss!**

Shaha's Aphorisms

**In surgery, the best  
instruments are fingers as  
they are connected to the  
brain.**

Shaha's Aphorisms

**When you don't know what to  
do in the operating room, use  
irrigation.**

**When you don't know what to  
do in the ICU, use steroids.**

Shaha's Aphorisms



**Four Stages in the life of a Surgeon: How to operate? When to operate? When not to operate? And how to dump the case on someone else.**

Shaha's Aphorisms

# **SNOPS: Society of Non-Operating Surgeons**

## Shaha's Aphorisms

# Case Presentation

- 45 year old principal with right thyroid nodule undergoes total thyroidectomy
- Size: 2.2 cm
- Final pathology – medullary carcinoma
- Further evaluation and treatment